Journal of Biomedical Sciences | ISSN: 2960-9356
Research Article Peer-review, Open Access

Comparative Histological Study of Different Age - Related Changes in the Respiratory System in Sprague-Dawley Rats

Shaimaa Hameed Hassan [1]

Abstract

The purpose of this study was to compare the gross histological characteristics of the trachea and lung between rats thirty postnatal and adults, as well as to define the developmental organization of these organs. Thirty healthy rats were divided into two sets of rats, each consisting of fifteen adults and fifteen 15 day old rats. Gross research; describe how the trachea and lungs develop; measure the trachea's length and diameter at various rat ages. Specimens from various tracheal and lung regions were used for histological investigations. They were fixed in 10% formaldehyde, embedded in paraffin wax, sectioned, and stained with Masson's Trichrome, routine stain, and AB. At 15 days of age, the trachea measured (1.820 ±0.013 a) cm in length and (0.11 ±0.008 a) cm in diameter while the adults rat was (3.9±0.08 a) and diameter (0.610±0.006 a), the number of ring of trachea in the 15 day postnatal was (18±0.30a) while the adult was (24± 0.34a)

The results of the statistical study also showed that the trachea's weight and length varied considerably (P>0.05) in the 15-day postnatal period. The findings showed that a 15-day-old postnatal's trachea was lined with pseudostratified columnar non-ciliated epithelium that included developing mucous glands, lamina propria, and loose connective tissue in the submucosa.

An adult rat's lamina propria is composed of robust connective tissue and is surrounded by ciliated pseudostratified columnar epithelium that contains seromucous glands. The adventitia inside the lacunae is composed of loose connective tissue with many elastic fibers, whereas the hyaline cartilage is composed of chondrocytes. Masson's Trichrome makes this observation.

Key words: Rat, Sprague-Dawley Rats, Development, Histological, Lung, Trachea, Cartilage.

[1] Department of the anatomy/ College of medicine, University of Sumer / Iraq

Introduction

The ventilation system, which controls the quantity of gases that can travel through the respiratory structure and outside air, depends on the respiratory system (1). Vocalization, body temperature regulation, olfaction, and breathing all require further respiratory activation, which involves gas exchange and conduction (2). The various anatomical parts that make up an animal's respiratory system are divided into conducting and respiratory components. Gas exchange is handled by alveoli, which constitute the system's terminal location (3). Gas exchange will be aided by the circulation of blood and air throughout a large area by a complicated network of blood vessels and airways (4). The trachea wall of the majority of domestic animals is composed of four layers: adventitia, submucosa, pseudostratified columnar epithelium, and musclelaris. These layers are supported by the unfinished hyaline cartilaginous rings (5). The physical features of the conducting and respiratory parts vary between animals and individuals. While the trachea plays a crucial role in breathing and intubation procedures using general anesthesia, morphometric investigations of the trachea and lung are essential. The trachea, bronchi, bronchioles, and lungs compose the lower respiratory system. The trachea is a flexible tube with mucosa lining the inside and cartilaginous rings joined by a fibromuscular membrane. Tracheal muscle fills the spaces between the several open, dorsally positioned C-shaped tracheal cartilages from various species that make up this structure (6). Both within and between species, the architecture of the respiratory tract varies (7). In the majority of mammals, the trachea's respiratory epithelium contains incomplete cartilaginous rings, a well-developed subtending adventitia, and is surrounded by a submucosa (8). The lacuna of the hyaline cartilage and the cartilage encircled by the perichondrium contain chondrocytes (9). A few sources on the evolution of the rat trachea and lung.

Materials and methods

Ethical approval: Every procedure was adhered to in compliance with animal care laws. The University of Sumer, College of Medicine used the animals' organs for research from March to September 2025 after they were slaughtered in compliance with ethical and animal care regulations.

Animals: - Used thirty Sprague-Dawley rats were employed in this investigation and separated into two groups, each with fifteen rats of two distinct ages. According to the classification, the first group was 15 days old, and the second group was adult. The animals were housed in the Department of Anatomy's Experimental Laboratory at the University of Sumer's College of Medicine. The animals were kept in a 12-by-25-meter enclosed area with water and air ventilation in well-furnished wood cages that measured 81 cm by 70 cm by 55 cm and complied with all laws. A 14 L:10 D system with 60 lux of light intensity, 14 hours of light, and 10 hours of darkness was employed to house the animals. On the farm, the average temperature was between 10 and 15 degrees Celsius. There was between 50 and 60 percent humidity (10). After that, they received a ketamine injection into their muscles to induce sleep. The trachea was observed and obtained by abdominal laparotomy and cranial displacement of the sternum. After being meticulously dissected while maintaining its complete morphology, it was cleaned with regular saline solution to get rid of any blood or other sticky residue. The trachea was found and photographed in its natural habitat using a digital camera. Following a 24-hour fixation in 10% formaldehyde, The tissue samples were embedded in paraffin wax after being dehydrated in graded alcohol and cleaned in xylol. Six micrometer-thick slices were cut from each paraffin block and stained with hematoxylin and eosin (H and E). to show the organ's histology components, Alcian blue (AB) to show the weak acidic polysaccharides, and Masson's trichrome to show the smooth muscle and collagen fibers (11).

RESULTS AND DISCUSSION

An annular ligament confirmed that the trachea of the Sprague-Dawley Rats resembled a flexible, hollow cylindrical tube made up of several rings of hyaline cartilage. It was filled with muscle and ring edges (fig. 1). The trachea is an elastic structure situated on the ventral side of the neck in the midline (fig. 7). It extends from the carina at the fourth thoracic vertebra to the cricoid cartilage of the larynx. At the level of the fourth thoracic vertebra, it then divided into the left and right major branches. Table 1 summarizes the

cartilaginous rings, which are C-shaped structures containing tracheal muscle at both ends (12). At 13 weeks, the trachea was longer on average than at 15 days, and there were fewer tracheal rings on average than at 15 days. The cross-section of the tracheal ring was either round or semicircular. Compared to 15 days, there were more rings in the tracheal and thoracic areas of the trachea. The trachea and right main bronchus had larger mean diameters than at 15 days, and the main bronchus had a larger diameter at 13 weeks than at 15 days. All structural features showed no significant difference ($P > 0.05$). The trachea was divided into the medial and thoracic sections based on topography.(13) Similar to the morphology of the thoracic cavity, the lung in both ages is represented by two reddish pink spongy tissues that encircle the heart (Fig. 7). The lungs' apex, base, dorsal, ventral, and caudal margins are present in both ages . The dorsal border was thick and rounded, while the ventral and caudal margins were flattened and pointed. The left lung apex was smaller and pointed, while the right lung apex was round and large. The diaphragmatic, medial, and costal surfaces of both lungs are convex and narrow. The lung is divided into several lobes by interlobar fissures. The apical, middle, caudal, and accessory lobes of the right lung are partially separated into two little lobes.(14) . The histological examination revealed that the mucosa lining the rats' trachea at 15 days of birth was primarily low columnar nonciliated these agree with (fig 2,3) (15), these results are similar to those observed in most mammalian species. The loose connective tissue known as the lamina propria was speckled with collagen, blood, and lymphatic fibers. These traits are similar to the histological traits of goats and cats (fig 1,2,6)(16). The tracheal mucous submucosal glands also grow as rat's age. The tracheal cartilage has two purple nuclei in addition to the matrix, and the interstitial material has a light blue hue with chondrocytes inside a lacuna. Collagen fibers with many elastic fibers made up the adventitia. (17) Demonstrates the mature rat trachea wall, which includes many goblet cells lining the mucosa and is bordered with pseudostratified ciliated columnar epithelium (fig 5). For the vast majority of mammalian species, our results are comparable to those published by (12). The collagen fibers, lymphatic, blood, and ser-mucous glands of the submucosa were all part of the flexible connective tissue known as the lamina propria (fig 1,6). These traits are comparable to those for the trachea of cats, sheep, and goats that are discussed in (17). The mucosa featured thin hyaline cartilage VI plates and a thin layer of muscle (fig 6) , giving it a somewhat folded appearance. These results are consistent with mice research by (13).

Table (1) Morphometric measurements of the trachea of Sprague-Dawley in different ages (cm) (Mean±SE).

Parameter	15 Days (Mean +SE)	Adult (Mean +SE)
Total length of trachea	1.820 ±0.013 A	3.9±0.08 A
Number of trachea ring	18±0.30	24± 0.34
Diameter of trachea	0.11 ±0.008 A	0.610±0.006 A

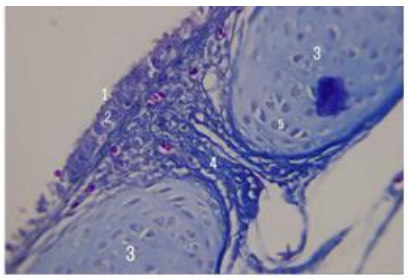

Figure (1) cross section that's show trachea in 15 day with Alcian blue (AB) (1) respiratory epithelium (2) goblet cell (3) trachea cartilage (4) smooth muscle (5) chondrocyte. 400X

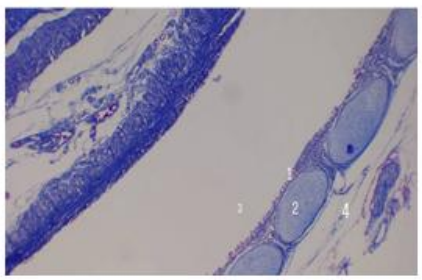

Figure (2) cross section that's show trachea in 15 day with Alcian blue (AB) (1) respiratory epithelium none ciliated (2) trachea cartilage (3) lumen (4) adventitia. 400X

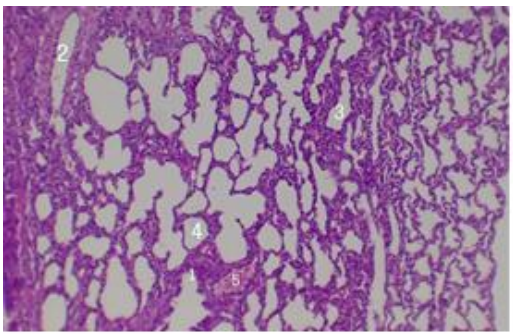

Figure (3) cross section that's show trachea and lung in adult rat with hematoxelin – eosin stain (HE) (1) respiratory epithelium (2) goblet cell (3) trachea cartilage (4) smooth muscle (5) chondrocyte. 100X

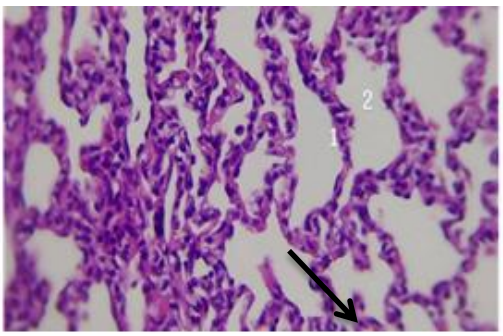

Figure (4) cross section that's show lung in adult rat with hematoxelin – eosin stain (HE) (1) alveoli simple squamous epithelium (2) alveolar duct (Black arrow) air saccules . 400X

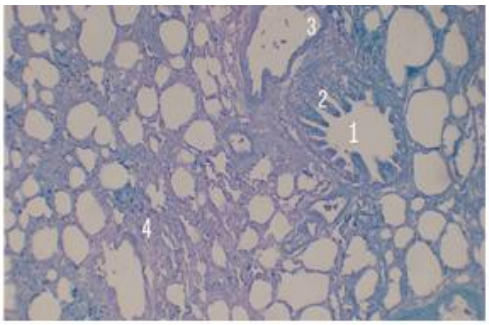

Figure (5) cross section that's show lung in 15day rat with Alcian blue (AB) (1) terminal bronchiole (2) Epithelium pseudostratified cuboidal (3)double capillary walls with air space (4) smooth muscle (5)alveoli single capillary walls 400X

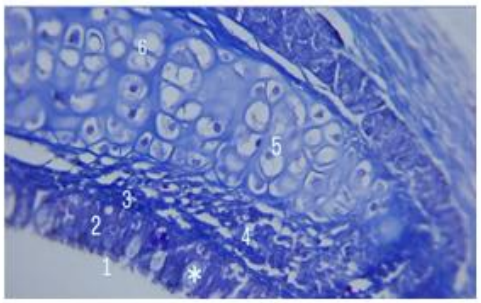

Figure (6) cross section that's show lung in adult rat with Masson's trichrome (1) ciliated cell (2) respiratory epithelium (3) sub mucosa (4) glands (5)tracheal hyaline cartilage (6)double nucleus lacuna (*) goblet cell 400X

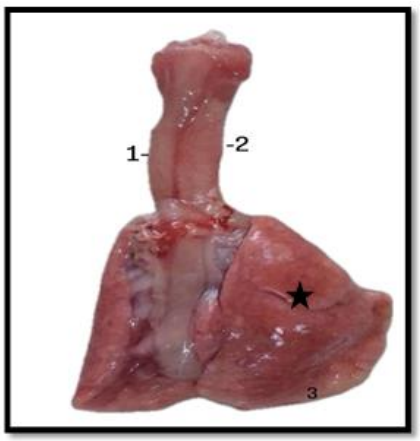

Figure (7) cross section that's lower respiratory system of rat (1) Esophagus (2) Trachea (3) Lung (black star) for oblique fissure of lung

References

1. Maton A, Hopkins JS, Johnson CW, McLaughlin MQ, Warner D, Lahart WJ. Human Biology and Health. Englewood Cliffs: Prentice Hall. 2010: 108-118.
2. Baba MA, Choudhary AR. Histomorphology of the pulmonary alveoli of goat (Capra hircus). Veterinary World. 2008;1(10):312.
3. Maina JN. The morphology and morphometry of the adult normal baboon lung (Papio anubis). Journal of anatomy. 1987; 150:229.
4. Yousif NH, Dawood MS. Morphometric Comparative Anatom ical Study Of Lower Respiratory Tract Between Sheep (Ovis aris) And Goat (Caprus hircus) in Baghdad provence. Kufa Journal For Veterinary Medical Sciences. 2019;10(2).
5. Steiner M. The physiological basis of respiratory disease: Hamid, Shannon, Martin: Published by BC Decker: ISBN: 1550092367 Price: £ 58.99 (Hardcover). Chronic Respiratory Disease. 2008;5(2):121.
6. Hussein, A. J., & Zahra, I. A. (2016). Morphological, Histological and Histochemical Study of trachea of One Hump Camel (Camelus dromedaries) In South of Iraq. Original article., pp. 19-25
7. Legaspi, M.S. (2010). Comparative safety respiratory pharmacology: Validation of a head-out plethysmography pneumotachometer testing device in male Sprague-Dawley rats, beagle dogs and cynomolgus monkeys. M.Sc. Thesis Universite de Montreal.
8. Auda, Diyaa A. (2007): Anatomical, histological studies of the respiratory system of the common J. quail (coturnix. coturnix L).M.S. Thesis Basrah Uni. Vet. Med. College.
9. Majeed, M. F., F.S. Al- Asadi, , A. N. Al. Nassir., and E. H. Rahi.(2009).the morphological and histologicalstudy of the caecum in broiler chicken. bas.j.vet.res.vol.8,no.1
10. Al-Ali, Majdi Faisal Majeed (2004), Ethnogeny, histological and biochemical in hepatic and taxa fishes. Laboratory as an indicator of pesticide poisoning. Doctorate thesis / Faculty of Science - University of Basrah, p. 30
11. Samuelson,D. A. (2007). Textbook of Veterinary Histology. W.B. Saunders Company. Pp: 231-232.
12. Yang, B.; Sijiu, Y.U.; Yan, C.; Junfeng, H.E.; Xinhua, J.I. and Andru, W. (2010) . Histochemical and Ultrastructural Observations of Respiratory Epithelium and Gland in Yak (Bosgrunniens) Faculty of Veterinary Medicine, The anatomical record. 293:1259–1269.
13. Nasser RA, Mirhish SM. Histological Study Of Lower Respira torsystem On Cats (Felis Catus Domesticus. L). In3rd Scien tific Conference-College Of Veterinary Medicine-University Of Tikrit 2016.
14. Koptev M, Pronina O, Danilchenko S, Avetikov D, Stavitskiy S. Histological features of rats' normal lung tissue.
15. Smolich, J.J., Stratford, B.F., Maloney, J.E., Ritchie, B.C., (1976). Postnatal development of the epithelium of larynx and trachea in the rat: scanning electron microscopy. J. Anat. 124, 657–673
16. Eurell J.A. & Frappier B.L.(2006). Dellmann’s Textbook of Veterinary Histology. 6th ed. Blackwell Publishing, Iowa, p.153-169.
17. William J. (1990): Color Atlas of Veterinary Histology. Lea &Febiger. pp 161–177