Journal of Biomedical Sciences | ISSN: 2960-9356
Research Article Peer-review, Open Access

Adult Cystic Nephroma Presenting with Situs Inversus and an Ipsilateral Staghorn Calculus: A Rare Case Report

Dr. Huda Fatehy Ali[1], Raghib Jassam Hameed[2]

Abstract

Background: Adult cystic nephroma is a rare, benign, multiloculated cystic renal neoplasm that predominantly affects perimenopausal and middle-aged women; it belongs to the mixed epithelial and stromal tumor (MEST) family of renal neoplasms according to the World Health Organization classification. Total situs inversus, a congenital mirror-image transposition of the thoraco-abdominal viscera, is itself an uncommon finding, and its coexistence with a renal neoplasm has rarely been documented, with only a small number of comparable cases reported worldwide.

Case presentation: We report a 35-year-old woman with known total situs inversus who was found on cross-sectional imaging to have a large, predominantly cystic, multiloculated right lower-pole renal mass measuring approximately 86.5 × 75.7 × 97.7 mm, together with an ipsilateral staghorn calculus and moderate pelvicalyceal dilatation. Contrast-enhanced CT angiography excluded vascular invasion and confirmed patent, normally opacified renal vasculature with bilateral accessory renal arteries. The patient underwent an uneventful right radical nephrectomy. Gross examination revealed a 10 × 8 × 6 cm multilocular cystic lesion containing a staghorn stone within the renal pelvis. Histopathology showed multiloculated cysts lined by flattened to cuboidal epithelium with intervening fibrous septa composed of bland spindle cells resembling ovarian-type stroma. Immunohistochemistry demonstrated stromal positivity for CD10, estrogen receptor and progesterone receptor. Surgical margins were free of tumor. These findings were diagnostic of adult cystic nephroma, a benign, indolent neoplasm, with no evidence of malignancy.

Conclusion: This case highlights an unusual convergence of two independently rare conditions adult cystic nephroma and total situs inversus in the same patient, complicated further by a coexisting staghorn calculus. It underscores the importance of thorough preoperative vascular and anatomical mapping in patients with situs inversus undergoing renal surgery and adds to the sparse existing literature correlating these two rare entities.

Keywords: Adult cystic nephroma; mixed epithelial and stromal tumor; situs inversus; staghorn calculus; radical nephrectomy.

[1] Department of Urology, Specialized Surgical Hospital, Medical City, Baghdad, Iraq

[2] Consultant Urologist, Specialized Surgical Hospital, Medical City Directorate, Baghdad, Iraq

*Corresponding email: hudaalhamadany110@gmail.com, raghib@consultant.com

Introduction

Adult cystic nephroma (also termed multilocular cystic nephroma) is a rare, benign renal neoplasm characterized by a well-circumscribed, multiloculated cystic mass composed of variably sized cysts separated by fibrous septa[1,2]. In the 2016 World Health Organization classification of renal tumors, adult cystic nephroma is grouped together with the mixed epithelial and stromal tumor (MEST) of the kidney as a single biological spectrum, distinct from the pediatric form of cystic nephroma, which is associated with DICER1 gene mutations [3,4,5]. The adult variant shows a marked female predominance, with reported female-to-male ratios as high as 8–9:1 in the fourth to sixth decades of life, and a peak incidence around 50–60 years of age, which together with stromal immunoreactivity for estrogen and progesterone receptors has led to the hypothesis of a hormonally driven pathogenesis [6,7].

Situs inversus is a rare congenital anomaly in which the thoracic and abdominal organs are arranged as mirror images of their normal position, with an estimated population prevalence of roughly 1 in 8,000 to 1 in 25,000. Renal neoplasms occurring in patients with situs inversus are exceptionally uncommon; the largest available systematic review identified only fourteen previously reported cases of renal tumors, almost all renal cell carcinomas, occurring in association with situs inversus between 1987 and 2024 [8]. To the best of our knowledge, no prior report has described adult cystic nephroma occurring in a patient with situs inversus. We present this case both for its rarity and to illustrate the additional preoperative anatomical and vascular planning that this combination of findings demands.

2. Case Presentation

2.1 Patient information

A 35-year-old woman with a known history of total situs inversus presented for evaluation of a right-sided renal mass identified on abdominal imaging. Relevant patient identifiers have been omitted from this report in accordance with journal and institutional confidentiality requirements, and written informed consent for publication of the clinical details and de-identified images was obtained from the patient.

2.2 Imaging findings

Contrast-enhanced CT angiography of the renal arteries (performed prior to surgery) confirmed situs inversus, with mirror-image transposition of the abdominal viscera. Both renal arteries were of normal caliber and course, without filling defect, thrombus or stenosis; bilateral accessory renal arteries of reduced caliber were present, predominantly on the right side, supplying the lower pole. There was no evidence of vascular engulfment by the right renal lower-pole lesion, and the abdominal aorta, its branches and both renal veins opacified normally.

The right kidney was normal in size and position with a lobulated outline and normal parenchymal thickness, but contained a well-defined, predominantly cystic lesion measuring 86.5 × 75.7 × 97.7 mm, exophytic from the lower pole, with multiple thin enhancing traversing septa. A large associated staghorn calculus measuring 42.7 × 53 mm (attenuation 435 HU) occupied the renal pelvis, with moderate dilatation of the pelvicalyceal system. The left kidney was normal in size, position and outline, with no focal lesion, no significant pelvicalyceal dilatation and no calculus.



Figure 1. Coronal contrast-enhanced CT image demonstrating situs inversus and a right renal cystic mass.

2.3 Therapeutic intervention

The lesion was too large to make a left-sided nephrectomy technically feasible, and the patient had a co-existent staghorn calculus and had to have the abnormal (mirror-image) vascular anatomy carefully mapped out, so that a right-sided radical nephrectomy was performed. The operation was uneventful, with safe identification and control of the renal vessels, including the accessory right renal artery, by means of preoperative vascular mapping using computed tomography angiography (CT angiography).

2.4 Gross pathological findings

The nephrectomy specimen consisted of the kidney and a segment of the ureter, ca. 4 cm long and 0.5 cm in diameter. When cut, a multilocular cavicular lesion with clear fluid and a staghorn stone within the renal pelvis was found in the mid and lower pole region (10 × 8 × 6 cm). CT revealed a predominantly lower pole renal mass, but gross pathological examination revealed that the mass was present in both the mid and lower poles. The rest of the kidney was unspectacular grossly, and the adrenal gland was not found within the specimen, indicating a renal origin. Multiple sections were submitted for histological evaluation of the cystic lesion, the junction of the cystic lesion with the renal sinus and perirenal fat, an area of separate paracortical cystic change, grossly normal parenchyma and the resection margins of the ureter and the vessels.

The microscopic and immunohistochemical results are presented. Microscopic and immunohistochemical results are presented.

A multiloculated cystic lesion with variably sized cysts lined by the presence of a single layer of flattened to cuboidal epithelium was seen in the histological sections. These intervening septa were fibrous stroma of varied cellularity with hypocellular and hypercellular areas, the latter containing bland, spindle-shaped cells, morphologically similar to those of ovarian-type stroma. A thin fibrous capsule bordered the lesion from the renal sinus and perinephric fat. No nuclear atypia, mitotic activity or areas of solid or infiltrative growth to indicate malignancy were detected.

The ovarian-like nature of the stroma was confirmed by diffuse positivity of the stromal component on immunohistochemistry for CD10, estrogen receptor (ER) and progesterone receptor (PR) (Table 2), and the diagnosis of adult cystic nephroma was made. The resection margin of the ureters and vascular were clear of tumour.

The histopathology showed a multiloculated cyst with variably sized cystic spaces divided by fibrous septa. The cysts were lined by one layer of flattened to cuboidal epithelium with bland spindle-shaped cells present in the stroma between the cysts, but with no significant change in nuclear atypia or nuclear mitotic activity (Figure 2).

The combined gross, microscopic and immunohistochemical findings were considered diagnostic of adult cystic nephroma a benign, indolent renal neoplasm with no histological evidence of malignant transformation.

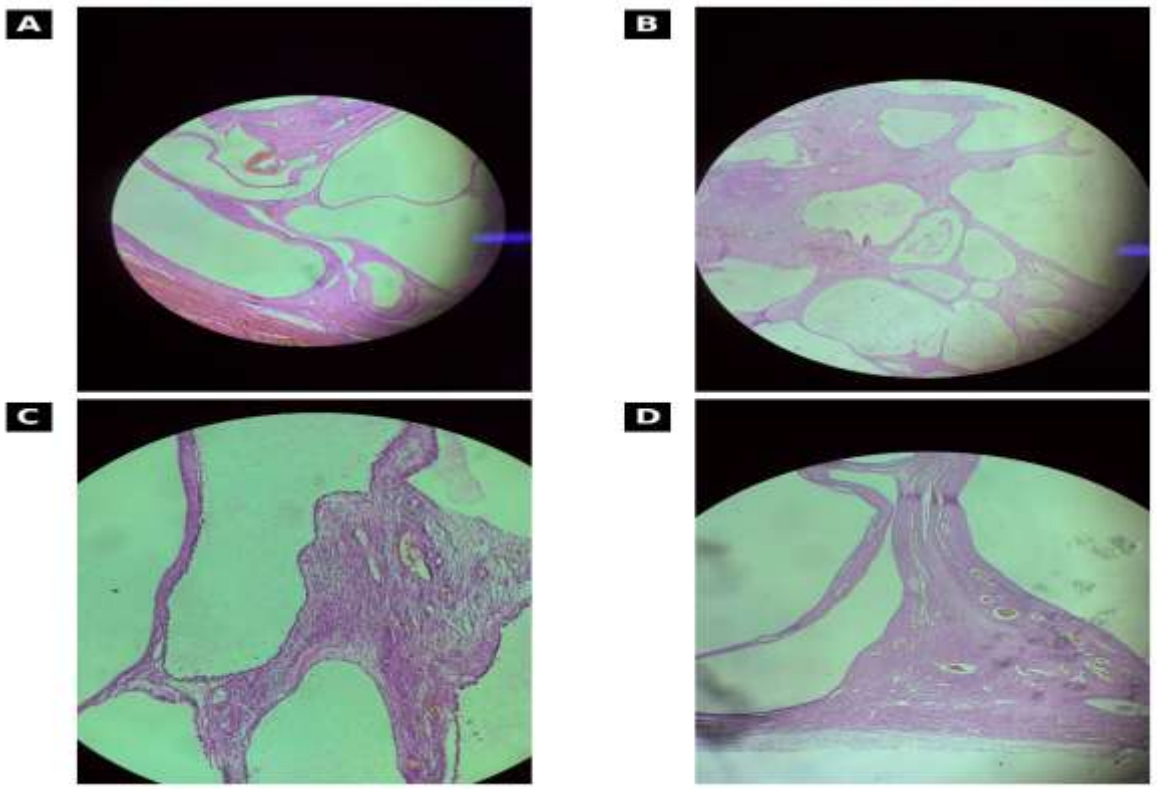

Figure 2. Histopathological Features of Adult Cystic Nephroma (Hematoxylin and Eosin Staining).

(A) Low-power view demonstrating the multiloculated architecture with variably sized cystic spaces. (B) Cystic spaces separated by intervening fibrous septa. (C) Higher-power view demonstrating the epithelial lining with underlying fibrous stroma. (D) Fibrous stromal septa containing bland spindle-shaped cells.

Table 1. Summary of clinical, radiological and pathological features

Age / Sex	35 years / Female
Presenting problem	Right-sided abdominal/flank mass, incidentally characterized on cross-sectional imaging
Relevant background	Total situs inversus (mirror-image thoraco-abdominal organ arrangement)
Imaging diagnosis	Right renal lower-pole cystic mass with a co-existing staghorn calculus
Surgical procedure	Right radical nephrectomy
Final histopathological diagnosis	Adult cystic nephroma (benign)
Immunohistochemistry	Stromal cells: CD10 (+), ER (+), PR (+)
Margins	Ureteric margin and vascular margin: negative
Outcome	Benign, indolent neoplasm; no evidence of malignancy

Table 2. Immunohistochemical profile of the stromal component

Marker	Result	Localization
CD10	Positive	Stromal component
Estrogen receptor (ER)	Positive	Stromal component
Progesterone receptor (PR)	Positive	Stromal component

3. Discussion

Cystic nephroma is a rare and benign renal neoplasm, which belongs to the spectrum of mixed epithelial and stromal tumour (MEST). A marked female predominance (around 90–100% of cases) and a median age at diagnosis of around 60 years have been reported in large clinicopathological series, which is well over the age of the patient described here [9]. These patients usually complain of vague symptoms of flank pain, hematuria or palpable mass, or the lesion is found incidentally as in this instance. In the imaging described above, there is a striking resemblance to cystic nephroma that is classically seen in adults, which primarily is a well circumscribed, multilocular cystic renal mass with thin enhancing walls and no solid enhancing component a Bosniak type III lesion.

Histologically, the diagnosis is based on the presence of variably sized, epithelial-lined cysts with cellular fibrous septa similar to ovarian stroma, which are also immunohistochemically positive for estrogen receptor, progesterone receptor and CD10, exactly as in the present case. In addition to this hormone-receptor expression pattern and the remarkable female predominance and perimenopausal age of the tumour, the long-held hypothesis is that adult cystic nephroma develops under hormonal influence, but this remains poorly understood. Partial or radical nephrectomy is curative if the tumour is small, localised and renal function is preserved and recurrence after complete removal is rare [10].

The second important point of this case is that the patient had total situs inversus. It is a congenital anomaly that occurs due to a failure in the process of left–right axis determination during early embryogenesis and is estimated to affect approximately 1 in 8,000 to 25,000 people. The association with a renal or retroperitoneal mass has definite surgical implications: the mirror-image relationships of the great vessels, renal pedicle and collecting system can make nephrectomy a much more difficult procedure, and accessory or anomalous renal vessels, which were present in this patient, have been reported more frequently in these patients [11]. However, only 14 cases of renal tumors in patients with situs inversus have been reported in the literature in the past 40 years, the majority of which were renal cell carcinoma treated with open or laparoscopic nephrectomy, and a few individual cases of renal cell carcinoma arising with situs inversus further highlight the need for careful three-dimensional vascular imaging by the surgeon to predict the presence of anomalous vessels and plan the surgical approach. This is the first report of a situs inversus (as far as we know) in association with adult cystic nephroma and not renal cell carcinoma, and therefore one of the few reports of a benign complex cystic renal lesion occurring in this anatomical association [12,13].

In this case the other significant feature is the concurrent presence of a staghorn calculus in the ipsilateral collecting system. Staghorn calculi can be complicated by UTI and can lead to damage of renal parenchyma and complicated imaging interpretation. The present calculus was not analyzed in terms of its composition [14,15]. The presence of a significant staghorn calculus further complicated radiological and surgical assessment and the cystic renal lesion. Preoperative CT angiography was important not only for characterization of the renal mass and exclusion of vascular invasion, but also for delineation of the mirror-image vascular anatomy in situs inversus which enabled safe surgical planning.

This case brings to the fore two teaching points which are important to clinical practice. First, if a woman with a predominantly cystic renal mass with thin enhancing septa outside the classically reported peak age range, consider adult cystic nephroma in the differential diagnosis of complex cystic renal lesions in addition to cystic renal cell carcinoma. Second, detailed preoperative cross-sectional vascular imaging is essential in all patients with situs inversus who will undergo renal surgery to discover the existence of anomalous or accessory vessels and safely plan the surgical approach, whether the renal lesion is benign or malignant.

4. Conclusion

We describe a rare instance of adult cystic nephroma, a benign mixed epithelial and stromal tumor of the kidney, occurring in a young woman with total situs inversus and a co-existing ipsilateral staghorn calculus. Complete radical nephrectomy, guided by careful preoperative vascular mapping, resulted in a curative outcome with negative margins and no evidence of malignancy on histopathological and immunohistochemical evaluation. This case adds to the very limited body of literature documenting renal neoplasms in patients with situs inversus and, to the best of our knowledge, this may represent the first reported case of adult cystic nephroma occurring in association with situs inversus, underscoring the value of individualized preoperative planning in this anatomically atypical patient population.

Declarations

Ethics approval and consent to participate: Not applicable (single retrospective case report); the case was managed according to standard institutional clinical care protocols.

Availability of data and materials: The de-identified data supporting this case report (imaging and histopathology reports) are available from the corresponding author on reasonable request.

Competing interests: The authors declare that they have no competing interests.

Funding: This case report received no specific grant from any funding agency in the public, commercial, or not-for-profit sectors.

Acknowledgements: The authors thank the radiology and pathology departments and all medical staff at Al-Shahid Ghazi Al-Hariri Hospital for Specialized Surgeries involved in the care of this patient.

Reference

1. Lane BR, Campbell SC, Remer EM, Fergany AF, Williams SB, Novick AC, et al. Adult cystic nephroma and mixed epithelial and stromal tumor of the kidney: clinical, radiographic, and pathologic characteristics. Urology. 2008;71(6):1142–1148.
2. Turbiner J, Amin MB, Humphrey PA, Srigley JR, De Leval L, Radhakrishnan A, et al. Cystic nephroma and mixed epithelial and stromal tumor of kidney: a detailed clinicopathologic analysis of 34 cases and proposal for renal epithelial and stromal tumor (REST) as a unifying term. Am J Surg Pathol. 2007;31(4):489–500.
3. Adult and pediatric cystic nephroma: an easily misdiagnosed renal tumor. Front Oncol. 2026.
4. Pathology Outlines. Adult cystic nephroma (kidney tumors). Available at: pathologyoutlines.com [accessed 2026].
5. Mixed epithelial and stromal tumor family of kidney (adult cystic nephroma, mixed epithelial and stromal tumor): retrospective clinicopathological evaluation. PMC10508419.
6. Bertini JE Jr, Boileau MA, Goldman SM. Renal cell carcinoma with situs inversus totalis. Urology. 1993;41(5):455–457.
7. Yan C, Li G, Li ZH, Wei ZH, Peng YX, Tao YF, Chong T, Wang ZL. Renal hilar tumor with situs inversus — a case report and systematic review. Urol Case Rep. 2025;60:102955.
8. Oake J, Drachenberg D. A case of renal cell carcinoma in a patient with situs inversus: operative considerations and a review of the literature. Can Urol Assoc J. 2017;11(5):E233–E236.
9. Dergamoun H, El Alaoui A, Boualaoui I, Sayegh H, Benslimane L, Nouini Y. Renal carcinoma and Kartagener syndrome: an unusual association. Case Rep Urol. 2020;2020:8260191.
10. Sekar, Thivya, and Neil J. Sebire. "Renal pathology of ciliopathies." *Pediatric and Developmental Pathology* 27.5 (2024): 411-425.
11. Guay-Woodford, Lisa M. "Cystic kidney disease." *Clinical Pediatric Nephrology*. CRC Press, 2016. 879-904.
12. Cass, Darrell L. "Fetal abdominal tumors and cysts." *Translational Pediatrics* 10.5 (2021): 1530.

13. Lennerz, Jochen K., et al. "Glomerulocystic kidney: one hundred–year perspective." *Archives of pathology & laboratory medicine* 134.4 (2010): 583-605.
14. Caliò, Anna, et al. "Cystic nephroma in adults: a clinicopathologic study of 46 cases." *The American journal of surgical pathology* 40.12 (2016): 1591-1600.
15. Eitler, Katalin, András Bibok, and Gábor Telkes. "Situs inversus totalis: a clinical review." *International journal of general medicine* (2022): 2437-2449.